

CODEN: JTOTDO 6(1) i-viii, 1-58 (1987)  
ISSN: 0731-3829

Journal of Toxicology

# **Cutaneous and Ocular Toxicology**

Volume 6

Number 1

1987

## EXCRETION OF A LIPOPHILIC TOXICANT THROUGH THE SEBACEOUS GLANDS: A CASE REPORT

*DAVID E. ROOT, M.D., M.P.H.\**

Sacramento, California

*GERALD T. LIONELLI, B.S.*

Foundation for Advancements in Science and Education  
Los Angeles, California

### Abstract

A 23-year-old woman was unable to work for 11½ months because of symptoms relating to toxic chemical exposure. The toxicants were amenable to removal through both the sebaceous glands and possibly the gastrointestinal tract by the Hubbard technique.

A 23-year-old woman was first examined in April, 1983, because of "chemical exposure," which she alleged had caused multiple subjective complaints, including sore throat, eye irritation, hoarseness, extreme malaise and lethargy, interrupted sleeping pattern and feeling "terrible all the time."

She had been employed in a maintenance capacity at a large manufacturing facility, where her job was to hose off the soot and ash that accumulated in the exhaust stack and on the filter pads of an oil-fired electrical generator. Although the contaminated washwater she used in this process was suspected of being toxic and consequently the source of her symptoms, this was never confirmed. However, the washwater was corrosive enough to dissolve the paint on cars parked nearby.

\*Address reprint requests to David E. Root, M.D., 1 Scripps Drive, Medical Building, Suite 201, Sacramento, California 95825.

For 6 months she performed this task without wearing any protective gear. In November, 1982, after feeling ill, she visited the plant nurse, who advised that she obtain her own wet-weather gear for protection. By December, 1982, the fear of contamination by the washwater—in light of the severity of her symptoms—required that she be removed from her job.

Her symptoms continued unabated and in February, 1983, she visited her family physician. He tested her carboxyhemoglobin levels and did a urinalysis for heavy metals. Her urine lead and mercury levels were  $4\text{ }\mu\text{g/L}$  and  $4\text{ }\mu\text{g/day}$ , respectively. Her blood lead level, blood carbon monoxide level, and findings on blood chemistry work-up were unremarkable. Forthwith, her physician elected to take her off work for 2 weeks while treating her with antibiotics for a urinary tract infection.

The initial medical examination performed in my office on April 13th, 1983, showed a slightly elevated temperature of  $99.6^{\circ}\text{F}$ , pulse rate of 96, and a normal blood pressure



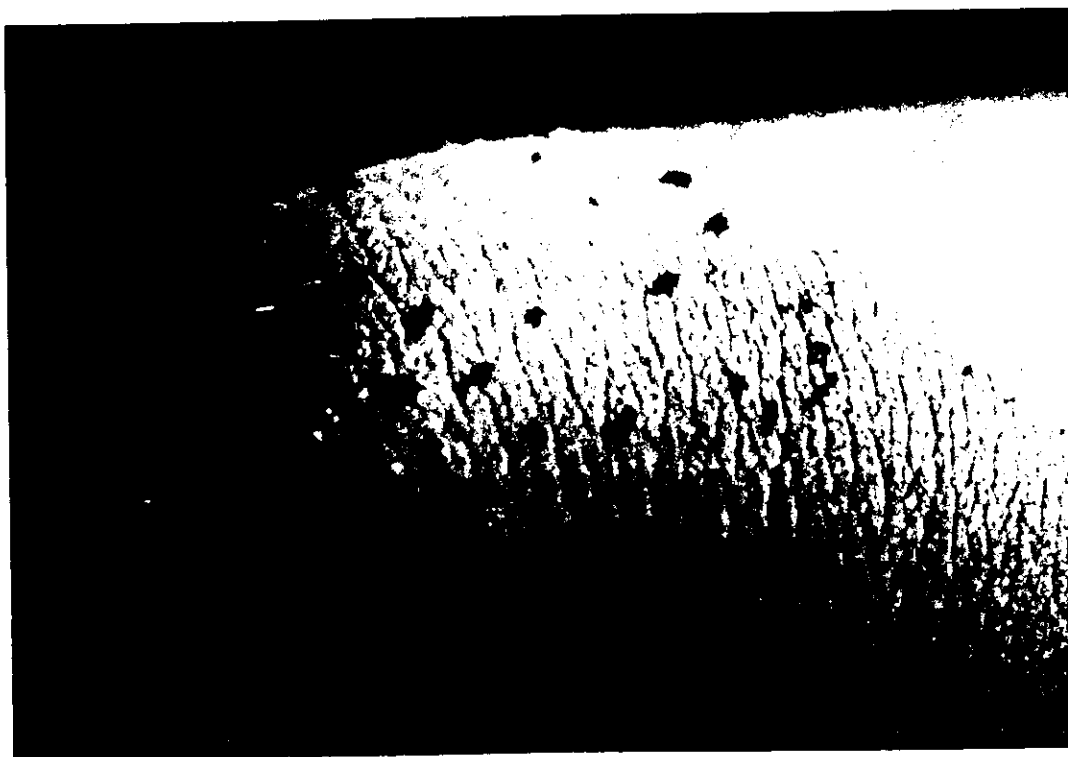
*Figure 1.* Right side of patient's face before treatment: Note the numerous pustular acne eruptions on the forehead and around the temple.

of 130/70. Mild to moderate pustular acne covered the lower part of her face and forehead (Fig. 1) and many acne comedones were noted on her upper back and chest. The pharynx was slightly hyperemic. Many (20-30) shotty lymph nodes were noted in the anterior and posterior cervical areas and in the inguinal and femoral areas. None were noted in the axillae. Her lungs were clear to auscultation and the liver and spleen were not palpable. Deep tendon reflexes were normal.

A throat culture was negative; however, a monospot test for infectious mononucleosis was ordered and found to be positive. She was therefore considered to have infectious mononucleosis causing the majority of her symptoms and was advised to remain off work and rest until her symptoms had cleared.

The patient returned on June 15, 1983, and was still complaining of lumps in her cervical lymph chains, tiredness, and malaise. Additionally, she reported an abnormal sleeping pattern: she slept approximately 4 hr during the day as well as 8 hr at night, yet remained very tired.

Physical examination showed five to six shotty lymph nodes in the cervical area, none in the axillae, and only a few small nodes in the groin area. No liver or spleen enlargement was present to palpation and a complete blood count was found to be



*Figure 2.* Patient's knee: Note the black exudate.



*Figure 3.* Right side of patient's face after treatment.

normal. Though she was still symptomatic she was released to return to work (light duty) as of June 20, 1983.

On July 11, 1983, a lymph node biopsy showed hyperplastic lymph tissue with no evidence of bacterial, viral, or parasitic infection.

The patient was reexamined on September 1, 1983. She again complained of tiredness, fatigue, and swelling on the left side of her neck. Physical examination revealed several small shotty nodes persisting in the left anterior and posterior cervical areas. Skin tests for coccidioidomycosis and tuberculosis as well as a repeat mononucleosis test were all negative.

Her continuing symptoms of malaise, lethargy, and lymphoid tissue hyperplasia were diagnosed as caused by low-level toxic poisoning. Chemical detoxification using the method developed by Hubbard was prescribed.<sup>1</sup> The program consisted of methods to enhance mobilization and excretion of fat-stored xenobiotics. This

involved aerobic exercise to promote lipid mobilization and increase circulation, heat stress to induce sweating and mobilize fat, and polyunsaturated oil supplements to aid in preventing the reabsorption of the bile, fat, and toxin emulsion found in the gastrointestinal (GI) tract as well as enhancing GI motility. Vitamin and mineral supplements were also used to aid in balancing the body chemistry. The treatment lasted 31 days.

On the fourth day of treatment a black substance began exuding from her pores (Fig. 2). This substance kept oozing from her skin during the sauna component of each day's treatment. This occurred in a continuously diluting manner until the completion of the program. Chemical analysis of the exudate was inconclusive. Further analysis has been initiated.

A posttreatment evaluation was done on November 21, 1983. A physical examination revealed that a majority of the acne pustules on the face had cleared (Fig. 3) and only three noninflammatory comedones remained on her back and chest. Examination of her neck showed only one small lymph node at the left supraclavicular area. The abdomen again was negative to palpation. While four to eight very small shotty inguinal nodes were noted, they were substantially smaller than at the pretreatment examination.

Removal of the toxic substances from her system was accompanied by remission of her subjective complaints as well. She no longer felt the extreme tiredness, malaise, and lethargy she had been experiencing since her exposure. Her hoarseness was gone and her sleeping pattern had returned to normal. She was authorized to return to full duty; as a precaution, she was advised to avoid exposure to the oily washwater.

### Reference

1. D. W. Schnare and P. C. Robinson, Body burden reduction of PCBs, PBBs and chlorinated pesticides in human subjects, *Ambio* 13(5-6):378, 1984.